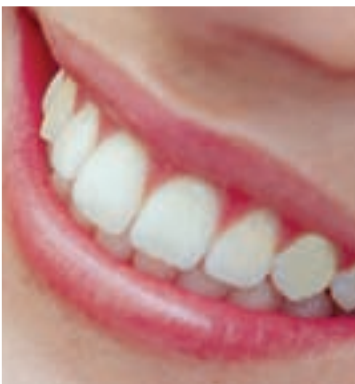



**GC
Tooth
Mousse
Portfolio**





Since its introduction in late 2002, GC Tooth Mousse has quickly become a firm favourite with dental professionals as a topical coating for teeth with a myriad of uses.

More and more applications are being found for Tooth Mousse and so we thought it would be useful to bring together some of the more common applications in one booklet.

If you already use Tooth Mousse, we hope you may find some additional applications by reading the clinical cases. If you have not yet tried this remarkable product, we hope the growing body of clinical case studies will encourage you to sample it.



CONTENTS

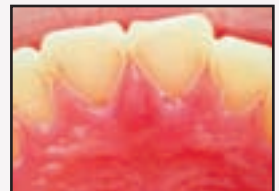Tooth sensitivity	3
Tooth whitening	4
Orthodontics	5
Fluorosis possibilities using microabrasion	6
Fluorosis treatment without microabrasion	7
Wine tasters and tipplers	8
Xerostomia	11
Erosion	12
Special needs patients	13
Final tooth polish	16

TOOTH SENSITIVITY

Prof. Laurie Walsh, University of Queensland






10 year old Emma complained of sensitivity of the palatal surface of her maxillary incisor teeth. They displayed a characteristic pattern of tooth loss suggesting dissolution by contact with gastric contents. The other areas of the dentition were unaffected and appeared clinically normal. Her general health was good, however she suffered from moderately severe asthma requiring daily use of a number of maintenance medications. She had a moderate intake of caffeine (140mg/day) from cola soft drinks. Her daily water intake was low, and she avoided drinking any sizeable volumes of cold water, since this caused a stomach upset. Careful questioning revealed Emma had suffered for some years from gastro-oesophageal reflux, a condition frequently associated with asthma. She noticed that her reflux was less severe on days when she had no cola soft drinks.

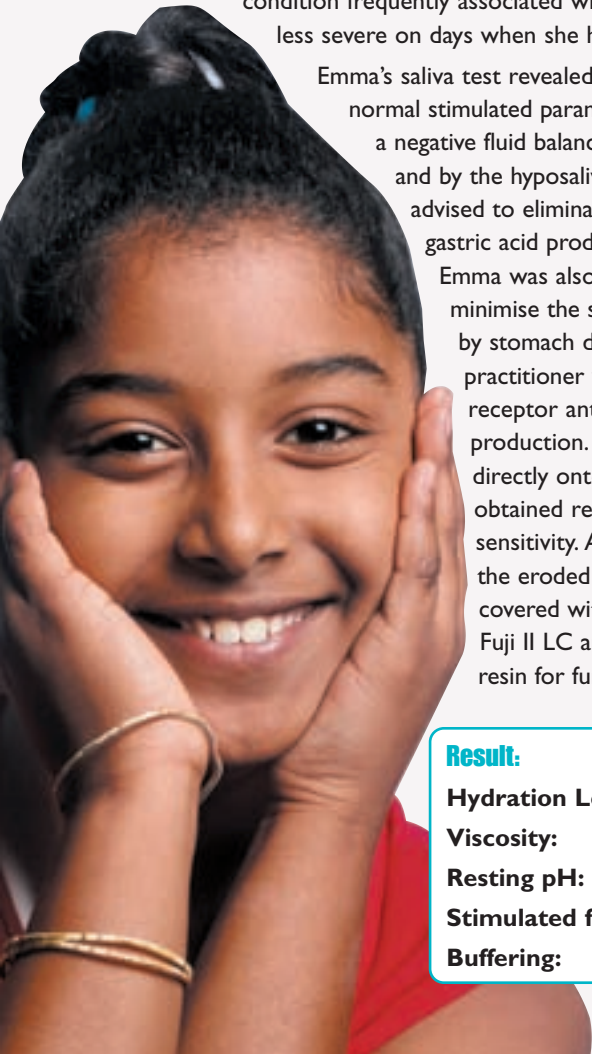Emma's saliva test revealed a low resting flow rate and acidic pH, but normal stimulated parameters. The low pH was explained partly by a negative fluid balance (from the diuretic effects of the caffeine) and by the hyposalivatory effects of her medications. She was advised to eliminate cola soft drinks, since caffeine stimulates gastric acid production and could exacerbate gastric reflux. Emma was also advised to drink warm water slowly, to minimise the stimulation of gastric acid secretion caused by stomach distension. She was referred to her medical practitioner who considered the value of using a H-2 receptor antagonist medication to suppress gastric acid production. Emma was advised to apply Tooth Mousse directly onto the eroded palatal surfaces and rapidly obtained relief from sensitivity. After 2 weeks, the eroded dentine was covered with a thin layer of Fuji II LC and composite resin for further protection.



Prof. Laurie Walsh

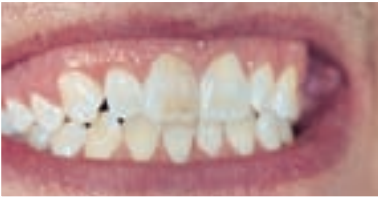Result:

Hydration Levels:	Low	
Viscosity:	Normal	
Resting pH:	5.6 Moderately acidic	
Stimulated flow:	6.0mL Normal	
Buffering:	10 Normal	

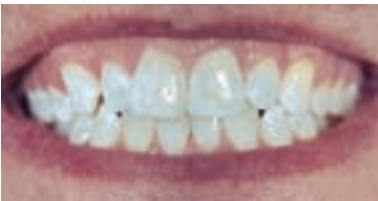



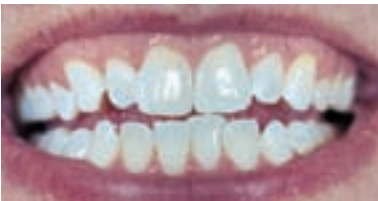COSMETIC MAKEOVERS FOR EVERY OCCASION



Before whitening



Immediately after the initial whitening appointment with heavy white staining on teeth still apparent



Two weeks after final whitening appointment and twice daily application of Tooth Mousse

Mr. C. Müller

TOOTH WHITENING

Dr. Brett Dorney, Pymble NSW

A difficult case of fluorosis on a 26 year old patient that required two in-surgery power bleaching appointments one month apart. Tooth Mousse was recommended prior to treatment to reduce sensitivity often experienced during this procedure and to give an improved final result.

In between appointments Tooth Mousse was applied twice daily.

“The white staining on these teeth was very intense but after treatment there was an aesthetic improvement and an acceptable result was achieved.”

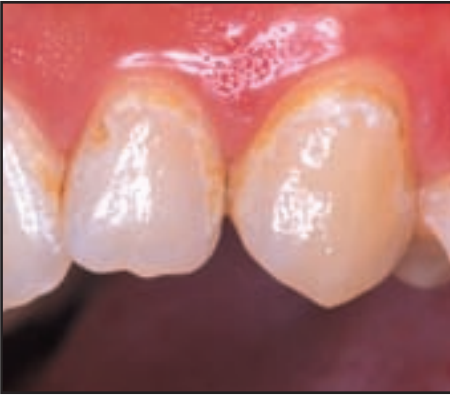Dr. Brett Dorney

ORTHODONTICS

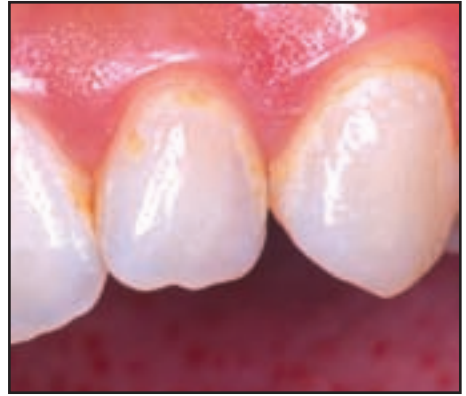Dr Hayashi Yokohama, Japan

Recaldent® CPP-ACP has been shown to have a dramatic effect on white spots especially for patients undergoing orthodontic treatment.

This series of clinical photographs was provided by an orthodontist who used a prototype paste containing 5% Recaldent® CPP-ACP following bracket removal.

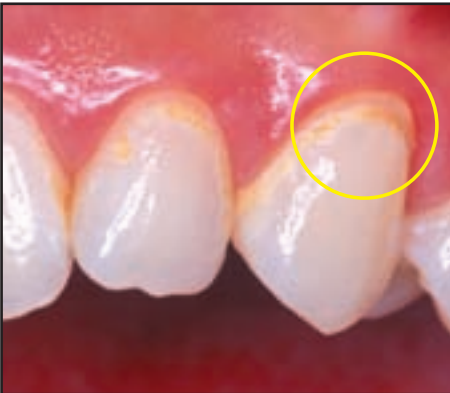

Immediately after bracket removal



A five minute twice daily application produced these results – at one month

Dr Hayashi Yokohama



After 3 months

In order to avoid the incidence of white spots, it is recommended to apply Tooth Mousse twice daily for the entire period that brackets are in place or an extra oral appliance is in use.



FLUOROSIS POSSIBILITIES USING MICROABRASION

Prof. Laurie Walsh, University of Queensland

CASE STUDY

A great combination for treatment of fluorosis

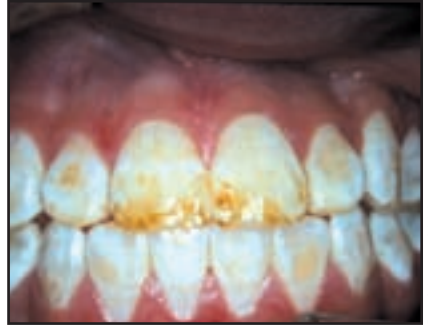In most cases of fluorosis accompanied by staining, enamel microabrasion is the preferred method of enamel treatment before application of Tooth Mousse.

The clinical technique used in this case was to etch the enamel for 120 seconds using 37% phosphoric acid, followed by prophylaxis using a slow speed handpiece and pumice to abrade the surface.

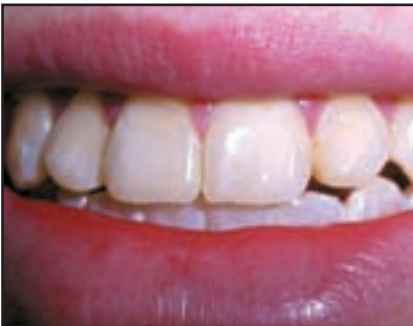Depending upon the degree of staining, this procedure may be repeated up to 3 times in one appointment to gain the required smooth (macroscopic) and porous (microscopic) surface, before application of Tooth Mousse.

After enamel microabrasion, the patient was given GC Tooth Mousse together with instructions on how to apply directly to the teeth each night just before sleeping, using a finger, and advised to leave in situ overnight.

After 6 weeks the teeth have a more normal appearance, with greater translucency and less opacity.



Prof. Laurie Walsh



Prof. Laurie Walsh

TREATMENT OF FLUOROSIS WITHOUT MICROABRASION

Prof. Laurie Walsh, University of Queensland

ANOTHER CASE STUDY

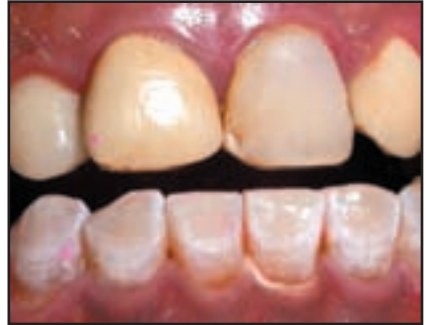A great combination for the treatment of fluorosis

In the case opposite we presented fluorosis accompanied by staining and suggested that enamel abrasion was the preferred method of enamel treatment before application of Tooth Mousse.

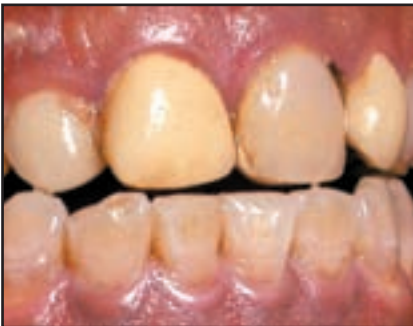This case illustrates that good results can also be achieved without microabrasion, provided that another method has been used to remove the surface pellicle and make the subsurface accessible to the action of Recaldent® CPP-ACP.

This patient has quite marked fluorosis on the lower anteriors that was reversed after just 2 weeks application of Tooth Mousse at home.

The enamel was prepared with a 5 second fine flour of pumice prophylaxis. Then a hydrogen peroxide 35% gel was applied as part of an in-office whitening procedure. The top image shows the situation immediately after removal of the gel.



Prof. Laurie Walsh



Prof. Laurie Walsh

A daily application of Tooth Mousse for two weeks provided the very acceptable result seen in this image. The above protocol can be used in cases where fluorosis has become more evident after in-office tooth whitening treatments.



INFORMATION AND ADVICE FOR WINE TASTERS

Dr. Gilbert Labour, Mawson ACT

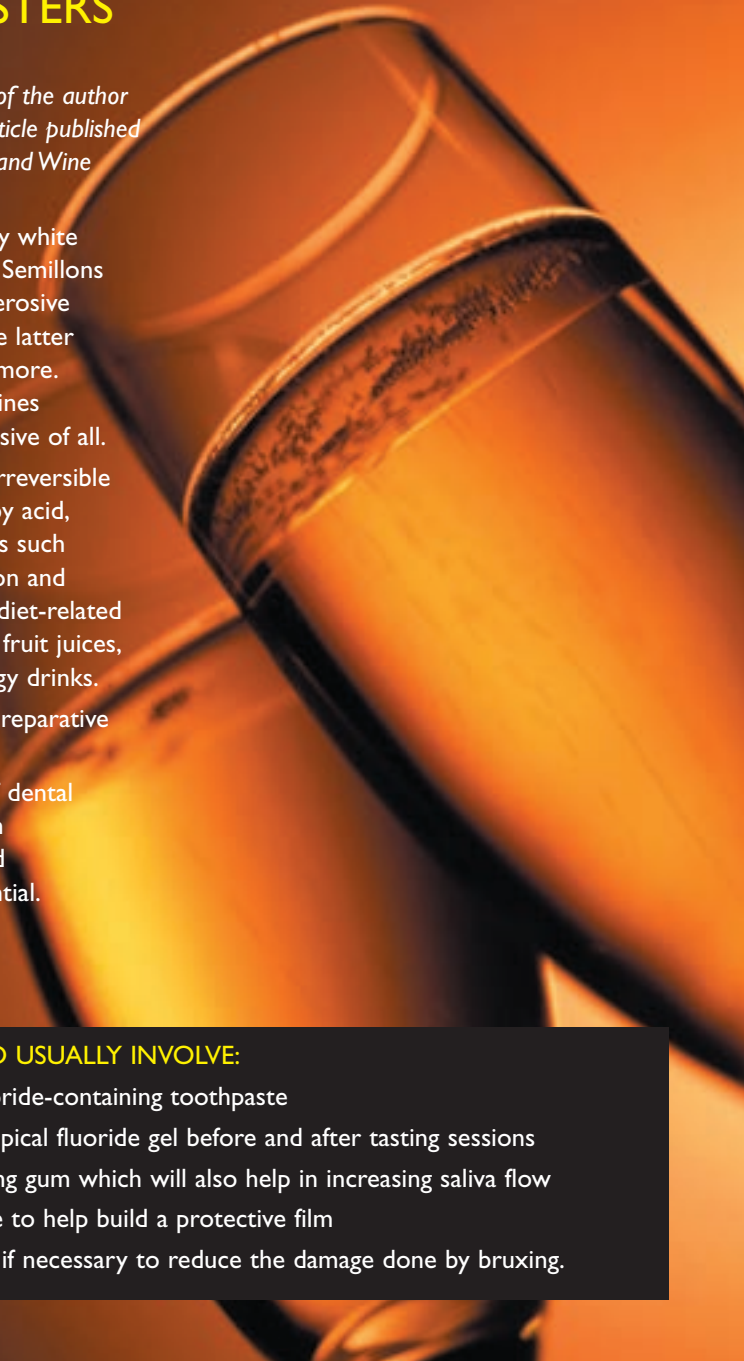
*Paraphrased with permission of the author
Dr. Gilbert Labour from an article published
in the Australian & New Zealand Wine
Industry Journal*

Wine is acidic, especially dry white wines such as Rieslings and Semillons and white wines are more erosive than red wines, although the latter stain the tongue and teeth more. However sparkling white wines are the most acidic and erosive of all.

Dental erosion means the irreversible loss of hard dental tissues by acid, either from intrinsic sources such as gastric reflux, regurgitation and vomiting, or from extrinsic diet-related sources such as wine, citric fruit juices, soft drinks and sports/energy drinks.

Treatment demands both a reparative and a preventive approach.

Once an acceptable level of dental health and hygiene has been restored, a maintenance and preventive program is essential.



MAINTENANCE WOULD USUALLY INVOLVE:

- regular use of a high fluoride-containing toothpaste
- use of a concentrated topical fluoride gel before and after tasting sessions
- use of Recaldent® chewing gum which will also help in increasing saliva flow
- use of GC Tooth Mousse to help build a protective film
- wearing of a night guard if necessary to reduce the damage done by bruxing.

PREVENTION FOR TIPPLERS AND WINE TASTERS

Saliva contains natural reparative elements such as calcium, phosphate and other minerals in trace quantities and is a very effective buffer to acid. However, during episodes of short and repeated acid attacks, such as experienced during wine tasting sessions, the saliva does not have adequate time to perform its reparative function. It is therefore not advisable to rinse too vigorously with water when tasting, as this would flush away the freshly demineralised tooth substance.

Rinsing with an alkaline medium (such as milk) and eating cheese should be an effective buffer, but will deaden taste buds and alter the finer perceptions required in proper wine appreciation. Therefore the use of a recalcifying chewing gum between tasting is beneficial.

Recently, the release of a new breed of remineralising materials has rapidly gained credence and popularity backed by clinical success.

The breakthrough came from research by Prof. Eric Reynolds and his team at The Dental School, The University of Melbourne. They isolated a specific milk protein, casein-phosphopeptide amorphous calcium phosphate (CPP-ACP) as a caries prevention and enamel remineralising agent. CPP is a sticky protein that binds and stabilises calcium and phosphate ions in an amorphous state. It readily binds to saliva pellicle, plaque, soft tissues and even to the hydroxyapatite component of enamel.

CPP-ACP maintains saturation levels of minerals, especially calcium and phosphate at the tooth surface, thereby depressing demineralisation and enhancing remineralisation. Ongoing research is presently pointing to the fact that CPP-ACP may also reduce the adhesion of caries causing bacteria *strep. mutans* and *strep. sobrinus* to salivary pellicle – an encouraging and very welcome development.





WHAT DOES IT ALL MEAN TO THE REGULAR WINE TASTER?

Dr Gilbert Labour, Mawson ACT

Whilst the application of fluoride agents has so far acted as a desensitiser, the new and exciting Recaldent® CPP-ACP breakthrough can potentially reverse some of the damaged dental structures which are exposed to short, repeated acid attacks, such as when wine sampling.



Interestingly, research comparing the effects of both fluoride 1000ppm and 2% CPP-ACP shows that, whilst fluoride causes a hypermineralised outer layer, CPP-ACP increases the mineral content within and through the subsurface layers.

Prof. Laurie Walsh, University of Queensland says: *Under acidic conditions, CPP-ACP releases calcium and phosphate ions thereby supersaturating the enamel, reducing demineralisation and increasing remineralisation. Complexes of CPP-ACP can also be delivered to plaque fluid by chewing gums, toothpastes and topical gels.*

WHAT TO ADVISE IN PRACTICAL TERMS?

Recommend/prescribe some of the Recaldent® CPP-ACP containing products.

Currently there is a range of Recaldent® chewing gums in adults' and children's flavours, as well as GC Tooth Mousse.

Use these products as well as topical fluoride and fluoride mouthwashes in order to maximise the longevity of the teeth.

Recaldent gum is very handy and beneficial between tastings of white wines as it immediately raises the pH of acidic saliva, making it difficult for plaque to adhere to tooth surfaces. Neutrafluor* 5000 toothpaste and acidulated phosphate fluoride rinses should also be used regularly.

Dr Gilbert Labour is a wine judge and reviewer for a number of food and wine magazines.

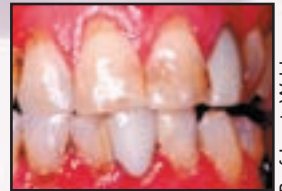

XEROSTOMIA

Prof. Laurie Walsh, University of Queensland






HELEN

Helen, a 55 year old school principal, complained of marked sensitivity to cold and air affecting many of the root surfaces of her teeth. This problem began six months ago but has become more severe over time. She has also noticed small cavitations appearing on some of the root surfaces. Coincidentally, Helen has noticed increasing dryness in both her mouth and eyes. Her general health is good and she has no other health problems. Clinical examination revealed that the exposed root surfaces of the maxillary anterior teeth are affected by erosion and are extremely sensitive to air and thermal stimuli. Root surface caries lesions are present on the lower anterior teeth. Saliva testing revealed an acidic salivary pH, both at rest and when stimulated. She also had depressed salivary buffering capacity. A lifestyle analysis revealed that Helen did not consume either caffeine or alcohol, and had a water intake of more than 2 litres per day. The combination of depressed salivary parameters and ocular dryness in a female patient of this age is suggestive of primary Sjögren's syndrome. Serological testing and a labial salivary gland biopsy confirmed this presumptive clinical diagnosis. In the light of her ongoing caries and erosion problems, Helen's home care program included GC Tooth Mousse twice daily, a saliva substitute, and intermittent chlorhexidine gel therapy once per week to suppress harmful bacteria. After restoring her cavitated areas with Fuji VII (or alternatively with a combination of Fuji VII and composite resin), Helen was then enrolled in a three-monthly maintenance program to ensure regular review of her status and to provide ongoing fluoride varnish applications to the at-risk tooth surfaces.



Prof. Laurie Walsh

Result:

Hydration Levels:	Low	
Viscosity:	Frothy, bubbly	
Resting pH:	5.6 Acidic	
Stimulated flow:	3.5mL Low	
Buffering:	4 Low	



EROSION

Prof. Laurie Walsh, University of Queensland

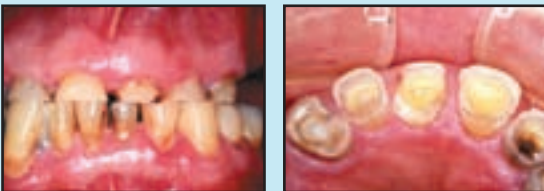ALBERT

Albert is a 72 year-old retired construction engineer. He had experienced rapid wear of his teeth over the previous 5 years, and was seeking cosmetic treatment. Albert suffered from obstructive sleep apnoea and had been using a continuous positive airways pressure (CPAP) mask at night as part of the management of this condition. Clinical examination revealed marked loss of tooth structure, with overclosure and forward posturing of the mandible to gain occlusal contact between the anterior teeth.

Saliva testing indicated an acidic resting salivary pH and also when stimulated, as well as a moderately depressed salivary buffer capacity. A lifestyle analysis revealed that Albert had a high intake of both caffeine (400 mg/day) and alcohol (5 standard drinks per day), but he drank little water. The diuretic effect of these two agents was substantial in his case, and added to the dehydrating influence of the CPAP therapy. Albert was recently diagnosed with insulin-dependent (Type 2) diabetes mellitus, which may have exerted an additional negative effect on his fluid balance. The low flow, pH and buffer parameters contributed directly to his current complaint of tooth wear through softening of the remaining tooth structure.

Albert's dental management included lifestyle modifications, to increase water intake and reduce his consumption of caffeine and alcohol. He was then placed on a remineralisation program using GC Tooth Mousse for 4 weeks, after which time his salivary parameters were re-checked and found to be normal.

He then underwent rehabilitation of his occlusion.



Prof. Laurie Walsh



Result:

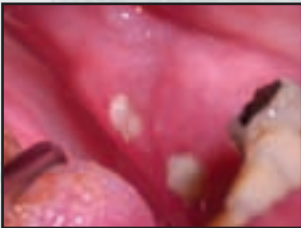Hydration Levels:	Low	●
Viscosity:	Sticky	●
Resting pH:	5.6 Acidic	●
Stimulated flow:	2.5mL Low	●
Buffering:	5 Low	●

SPECIAL NEEDS PATIENTS

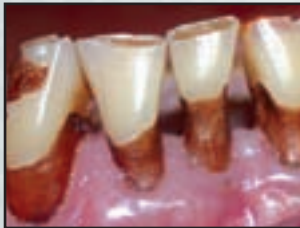Dr. Liz Coates, University of Adelaide

FOLLOWING RADIATION TREATMENT

JACK is 79 and underwent radiation for a palatal tumour in December 2002. Initial fluoride application commenced immediately following treatment but was discontinued in June 2003 due to allergy concerns, because he had developed significant rashes, erythematous areas and spontaneously developed osteoradionecrosis that had to be treated with hyperbaric oxygen. In June 2004 Jack was prescribed GC Tooth Mousse. Since then he has been able to sleep continuously for 6 hours each night, whereas previously he would awaken every two hours due to dryness of the teeth and mouth.



Bony sequestra post radiation treatment



15 months after radiation treatment

Dr Liz Coates

“Initially we had expected it would take months or years before the benefits of Tooth Mousse could be positively evaluated in relation to a home care protocol, but the quality of life improvement was almost immediate.”

Dr Liz Coates

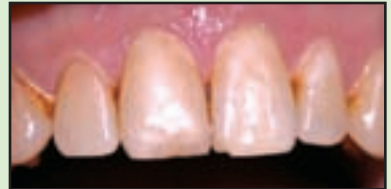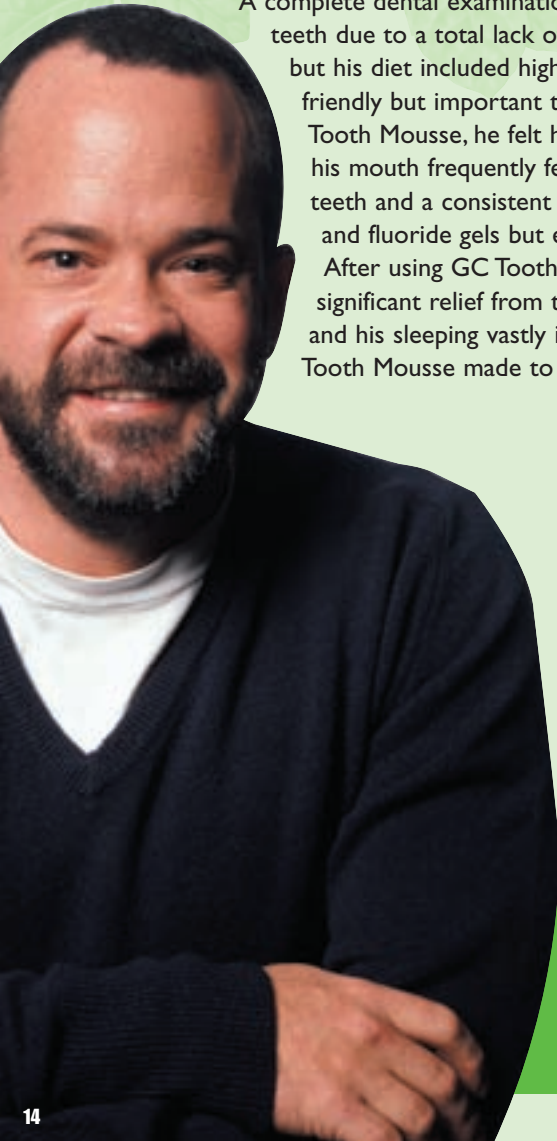


ASSISTING IN THE TREATMENT OF AIDS

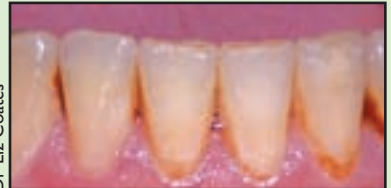Dr. Liz Coates University of Adelaide

RICHARD is 33 years old and suffering from AIDS. He has an extremely dry mouth due to HIV and the number of different medications required to fight the virus. Unfortunately this means a daily regime of many tablets and other medications to resist ordinary pathogens and avoid pneumonia or TB.

A complete dental examination revealed many carious and decalcified teeth due to a total lack of saliva. Richard's oral hygiene was very good but his diet included high calorie substances that were not tooth friendly but important to sustain life. Prior to being prescribed Tooth Mousse, he felt his oral health was fair, but commented that his mouth frequently felt uncomfortable due to dryness, sensitive teeth and a consistent bad taste. He previously used artificial saliva and fluoride gels but experienced difficulty in sleeping and eating. After using GC Tooth Mousse for a short period, he received significant relief from the oral discomfort, was able to eat better and his sleeping vastly improved. He was delighted at the difference Tooth Mousse made to his life.



Due to lack of saliva, Richard's teeth had become very sensitive, decalcified and developed root surface caries.



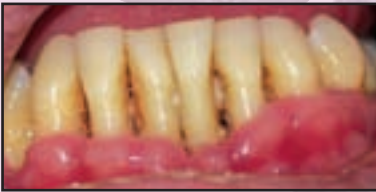Dr Liz Coates

“Almost immediately patients that had been prescribed Tooth Mousse reported a significant improvement in the quality of their lives.”

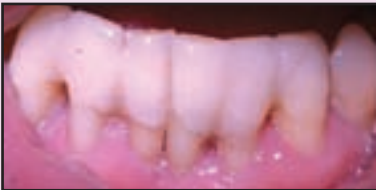Dr Liz Coates

PETER was 28 when diagnosed with HIV in 2000. He had developed extensive acute periodontal disease related to the viral infection that contributed to enormous bone loss especially of the lower anterior teeth resulting in grade four mobility of teeth.

The extensive area of exposed tooth root surfaces meant significant changes were necessary in his diet. At that time he was working in the hospitality industry but additional stress contributed to further deterioration of his general health. The teeth were splinted for extra stability and Peter was given GC Tooth Mousse for a trial period to alleviate sensitivity. He considered his general wellbeing was good, although his sleep was sometimes interrupted by night time mouth dryness and oral discomfort. Peter found Tooth Mousse to be very effective and pleasant tasting and his oral comfort improved dramatically.



Before splinting the lower anteriors, Peter had significant eating difficulties. Tooth Mousse was recommended to alleviate the sensitivity.



Dr. Liz Coates

After using Tooth Mousse, he was able to eat almost anything. He noticed that plaque and debris accumulation was also reduced.

“This excellent result was immediate and unexpected. The cost was not excessive in relation to the perceived benefit.”

Dr Liz Coates



FINAL TOOTH POLISH



A number of clinicians have advised Tooth Mousse provides an excellent final tooth polish after placement of a glass ionomer or composite restoration.

Simply place a layer of Tooth Mousse over the restoration and leave for one or two minutes. Then gently polish the restoration and other coated areas using a rubber cup at low speed.

Patients say they can really feel the difference where Tooth Mousse has been applied and the tooth itself also appears to be brighter and more vital.



Other Recaldent® products currently available

- Recaldent® Pellets – new packing and more flavour
- Recaldent® Kids
- New Recaldent® Mints – available only with Fuji IX GP Capsules (Australia/NZ)



GC Asia Dental Pte Ltd
Changi Logistics Centre
19 Loyang Way #06-27
Singapore 508724
Tel 65 + 6546 7588 Fax 65 + 6546 7577
<http://www.gcasia.info>

©GC Corporation 2004

Recaldent® is used under licence from Recaldent Pty. Limited.
Recaldent® CPP-ACP is derived from milk casein and is lactose free.
It should not be used on patients with milk protein allergies.

* Not a trademark of GC Corporation or Recaldent Pty. Ltd.

Reorder code: 0410-121

